

Dermatofibrosarcoma protuberans of the head and neck: case report using combined surgical approach

R R Patel, Medical Officer, M Giaquinto-Cillers, Head of the Department, H Reiner, Medical Officer, T Potgieter, Medical Officer, G Steyn, Medical Officer
Department of Plastic and Reconstructive Surgery and Burns Unit, Kimberley Hospital Complex

Correspondence to: ravin.patel.3@gmail.com

Keywords: dermatofibrosarcoma protuberans, acellular dermal matrix, Integra, head and neck reconstruction, deltopectoral flap

Abstract

Introduction: The surgical and reconstructive management of malignant tumours of the head and neck have always presented unique challenges, particularly as they occur in such a cosmetically significant area. The aim for surgical resection emphasises adequate oncological control of the tumour, which often leaves large soft tissue defects requiring complex surgical techniques for reconstruction. In this report the authors present a case of a dermatofibrosarcoma protuberans in the head and neck which was resected, leaving a large superficial soft tissue defect in the neck and face. Reconstruction and closure of the defect was achieved with a combination of a regional fasciocutaneous flap, dermal regeneration template and later skin grafting.

Materials and methods: A 65-year-old female patient presented to the Kimberley Hospital Complex. The patient underwent a wide local excision of a head and neck dermatofibrosarcoma protuberans by the Department of Maxillofacial Surgery followed by surgical reconstruction by the Department of Plastic and Reconstructive Surgery.

Results: The combined approach of a regional fasciocutaneous flap, dermal regeneration template and skin graft were used to achieve an aesthetically adequate closure of the large wound left after excision of the head and neck tumour.

Conclusion: This presented technique provides a good reconstructive option for the management of soft tissue head and neck tumours which leave large defects following resection with curative objectives, particularly in settings such as ours where more complex reconstructive techniques are limited by a combination of factors.

© Medpharm

Wound Healing Southern Africa 2017;10(1):6-11

Introduction

The surgical and reconstructive management of malignant tumours of the head and neck has always presented unique challenges, particularly as they occur in such a cosmetically significant area. The aim for surgical resection emphasises adequate oncological control of the tumour, which often leaves large soft tissue defects requiring complex surgical techniques for reconstruction. In this report the authors present a case of a dermatofibrosarcoma protuberans (DFSP) in the head and neck which was resected, leaving a large superficial soft tissue defect in the neck and face. Reconstruction and closure of the defect were achieved with a combination of a regional fasciocutaneous flap, dermal regeneration template and later skin grafting.

Case report

A 65-year-old woman was referred to the Department of Maxillofacial Surgery at Kimberley Hospital from a private family practitioner in Prieska in the Northern Cape with a large right-sided facial mass. After attempts to obtain a tissue diagnosis from incisional biopsies proved difficult due to the vascularity of the lesion, and after various

staging investigations, such as computed tomography scans, revealed that the mass was localised to the facial region, a plan to perform an excisional biopsy was considered by the Department of Maxillofacial Surgery and she was referred to the Department of Plastic and Reconstructive Surgery for assistance with closure/reconstruction of the defect that would be created from an excisional biopsy.

The patient was seen at the Plastic and Reconstructive Surgery Clinic and an initial clinical assessment was performed. The patient was a retired pensioner with no significant past medical or surgical history. She had no family history of note, however she was a tobacco pipe smoker. She initially presented to health services three months prior, with a three year history of a progressively enlarging right-sided facial mass. Clinical evaluation and measurements performed in the plastic surgery clinic showed that the mass was approximately 98 x 143 x 121 mm with a lobulated and highly vascular appearance extending from the right maxilla, right nasolabial fold and right pre-auricular area down onto the right anterior neck as far as the superior aspect of the right clavicle (See Figures 1–3).

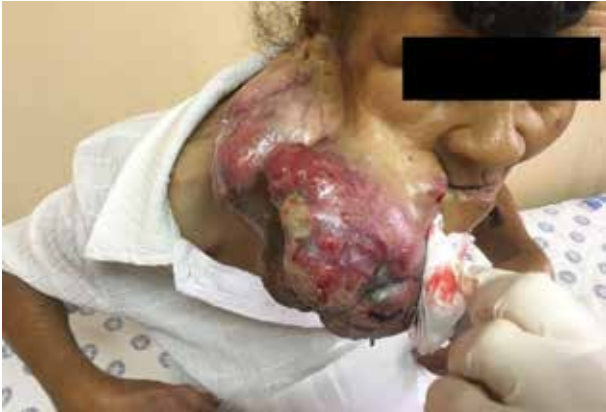

Figure 1

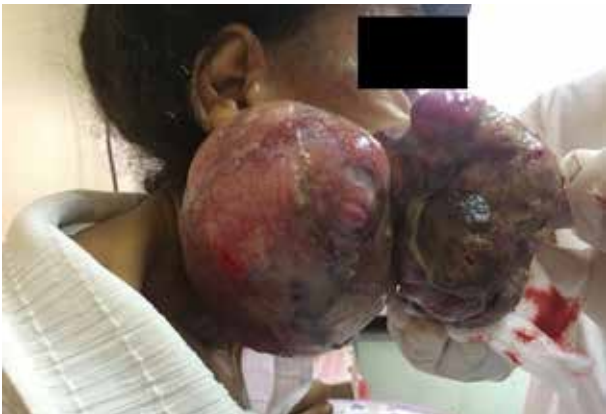

Figure 2

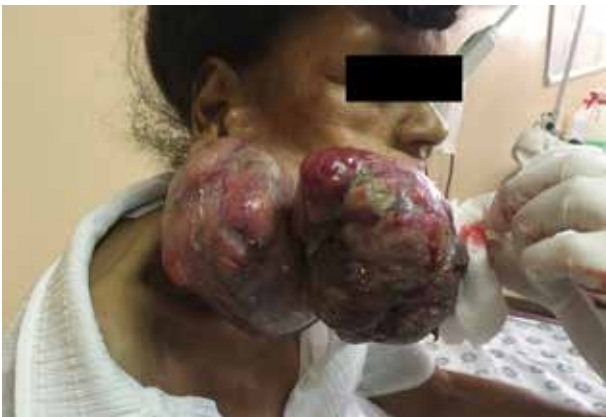

Figure 3

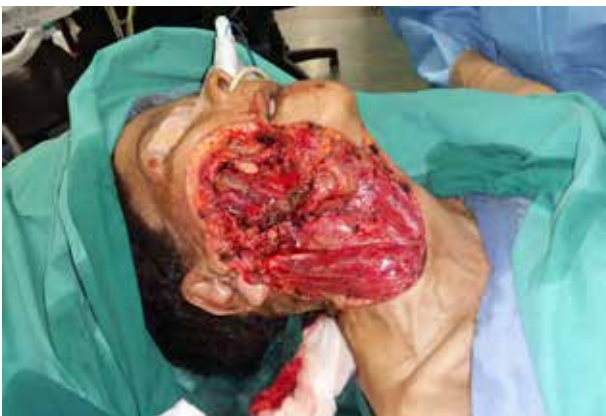

Figure 4

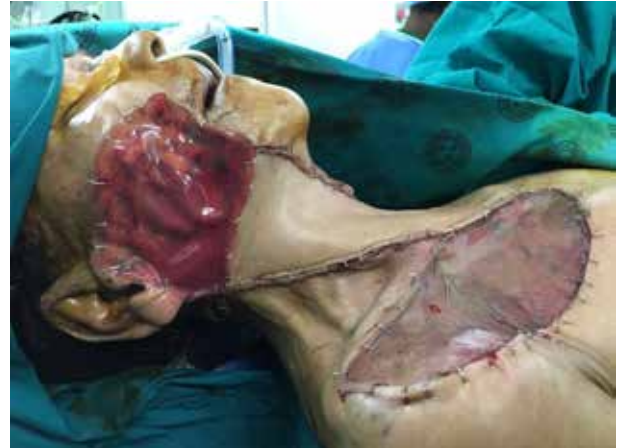

Figure 5

Two weeks later, the patient was taken to theatre for excision of the mass by the Department of Maxillofacial Surgery followed by reconstruction by the Department of Plastic and Reconstructive Surgery. A complete and uneventful excision of the mass was performed which left a large defect on the right side of the face and neck. The defect extended from the right nasolabial fold, right maxilla and right pre-auricular area down to the right anterior neck from the midline to the supraclavicular area. There was exposure of the sternocleidomastoid and masseter muscles as well as the parotid and submandibular salivary glands and facial nerve (Figure 4). Reconstruction and closure of this defect used a combined approach which involved raising a fasciocutaneous deltopectoral flap from the right side which measured 16 x 6.5 cm and advancing the flap to fill the defect in the neck up to the angle and edge of the mandible. A split thickness skin graft (STSG) was then harvested from the right thigh to close the defect created by the deltopectoral flap. The defect on the right cheek was finally closed using Integra® (Baroque Medical) which was cut to fit the shape of the defect (Figure 5). The dressings used were Adaptic® (Systagenix) and Acticoat® (Smith and Nephew) over the Integra® and STSG, and Adaptic® and Bactigras® (Smith and Nephew) over the deltopectoral flap.

Postoperatively, the patient was transferred to the intensive care unit (ICU) for further management and after an uneventful two-day stay in ICU she was discharged to the wards. On day five post operation, her wounds were reviewed and her dressings changed. On day seven post operation another dressing change was done and it was noted that her wounds were healing well and therefore alternate clips and sutures were removed. On day nine post operation her wounds continued to improve with no evidence of infection and all of her clips and sutures were removed. She then continued to receive dressing changes every two days; the dressings used were Bactigras® to all the wounds and Actisorb® (Systagenix) which was applied only to the Integra® (Figures 6–9).

Histological evaluation of the resected lesion was performed by the Pathology Department at Kimberley Hospital and in consultation with the Department of Histopathology at the University of the Orange Free State. After both departments had assessed the specimen, the resection margins were deemed satisfactory and no further excision or radiotherapy would be necessary.

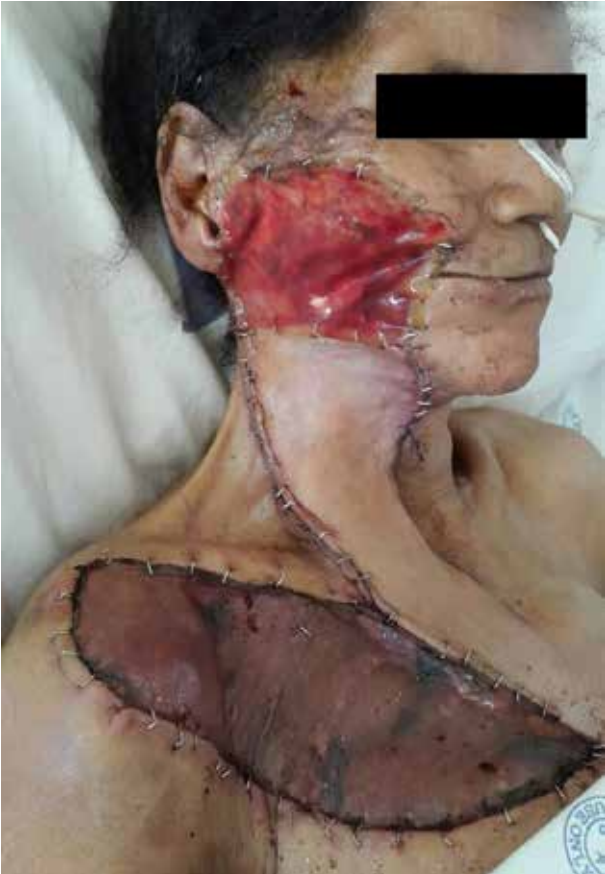

Figure 6

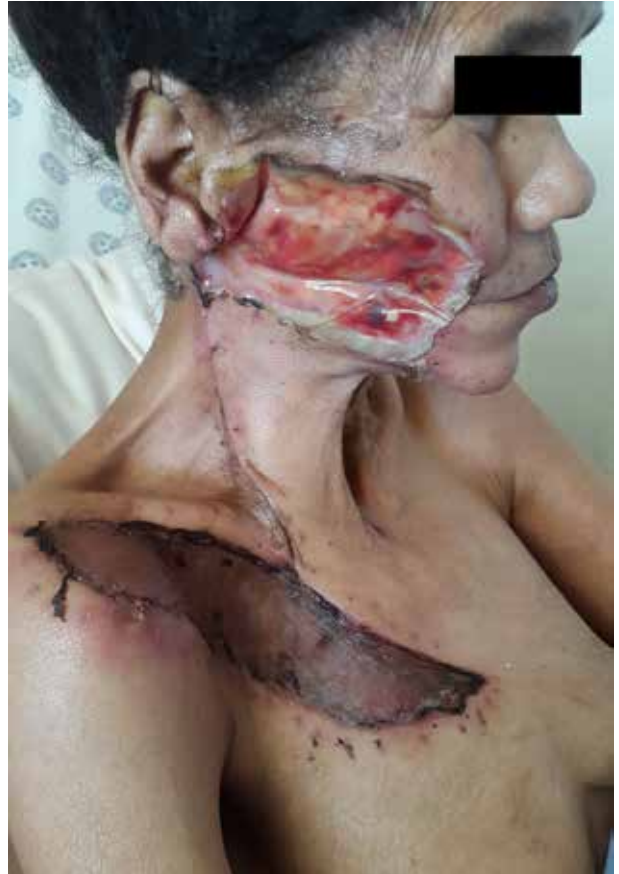

Figure 8. Day 16 Post Op

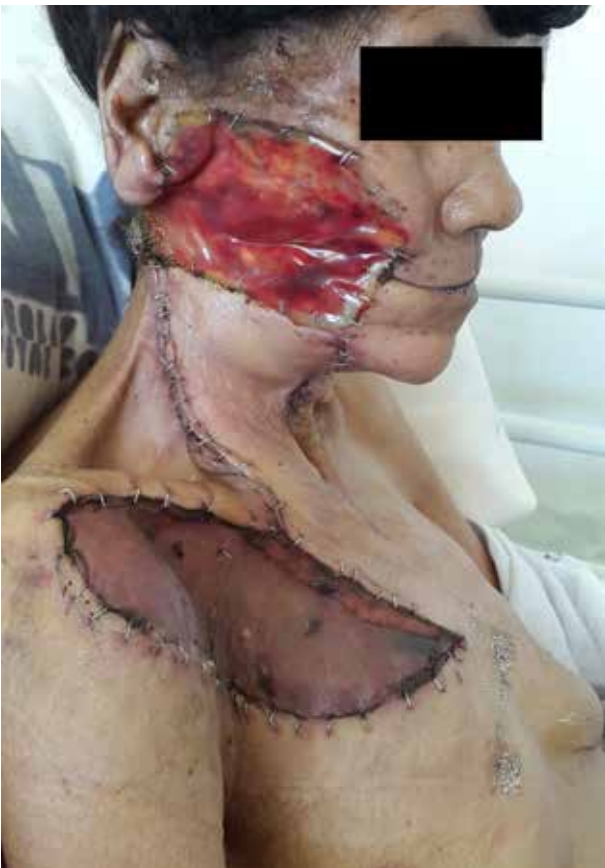

Figure 7. Day 8 Post Op

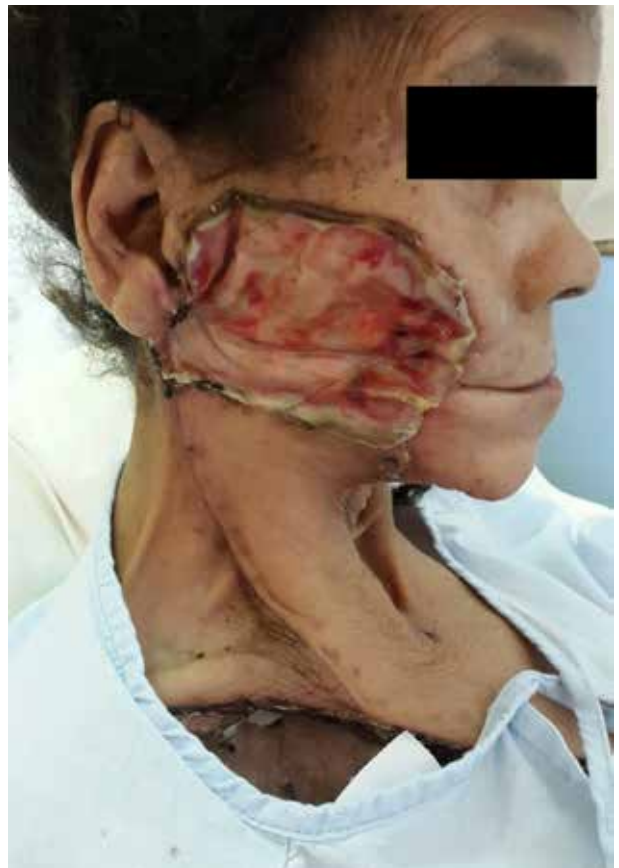

Figure 9. Day 21 Post Op

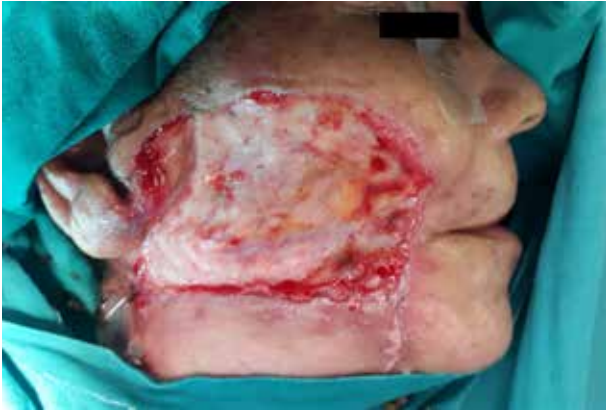

Figure 10. NeoDermis

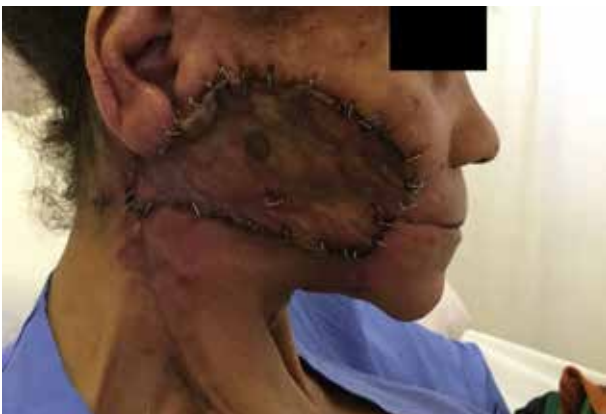

Figure 11. Day 5 Post Op - FTSG

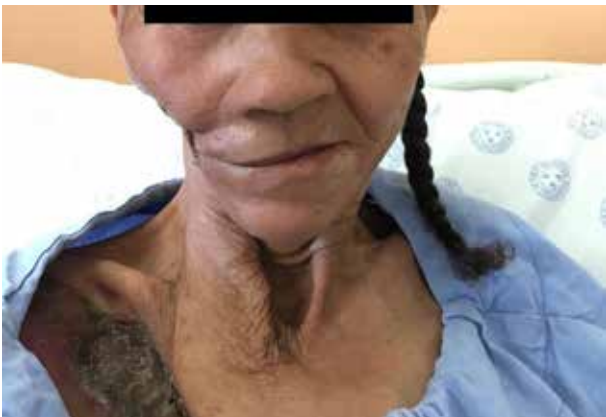

Figure 12. Day 5 Post Op - FTSG

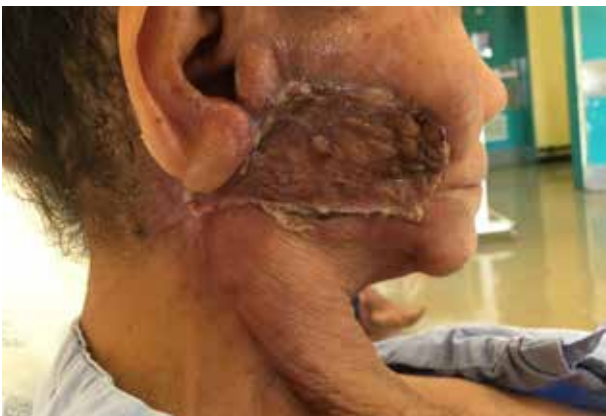

Figure 13. Day 9 Post Op

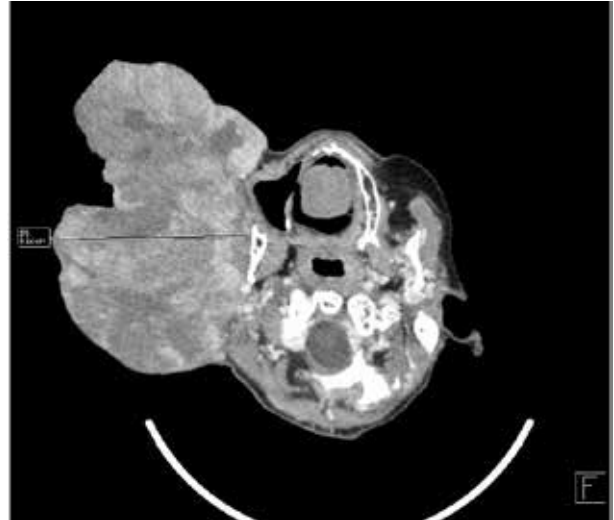


Figure 14. CT Scan

On Day 21 post operation, the patient was taken back to theatre for final closure of the wound on her right cheek. A full thickness skin graft (FTSG) was harvested from the inferior abdomen and applied to the right cheek after the silicone layer of the Integra® had been removed. The FTSG was secured using clips and the donor site was closed primarily. The FTSG was dressed with Adaptic® and Bactigras®. The patient's FTSG was reviewed on day five post procedure and dressings and wound reviews were done every two days thereafter (the clips were removed on days seven and nine). On Day 18 post FTSG to the right cheek, the patient was discharged home with all of her wounds healed (Figures 10–13).

Discussion

This case report adds to an already established body of work regarding acellular dermal matrices (ADM) and their use in the reconstruction of complex soft tissue defects, with limited vascular supply often following trauma, burns and oncological surgery.¹ The various benefits of the use of an ADM include immediate closure of wounds, minimal donor site morbidity, reconstruction which remains pliable and resistant to hypertrophic scarring and contracture, and finally a good functional and cosmetic outcome.¹⁻⁶

For wounds where there has been extensive skin loss or damage, in which both epidermal and dermal skin layers are lost, wound healing using only dressing materials or delivery of active agents alone is not viable. Therefore, alternative solutions using either artificial or bioengineered skin substitutes are required to allow the necessary regeneration and replacement of lost tissue.⁷ Tissue-engineered skin substitutes function largely because of the ability of fibroblasts and keratinocytes to spontaneously form three-dimensional structures similar to skin.

Unlike dressings, tissue-engineered skin substitutes are made up of fabricated biomaterial polymer matrices (such as collagen) that act as scaffolds for engineered skin substrates, which grow to actively replace lost tissue. The scaffolds possess mechanical and anatomic characteristics which act to mimic the tissue (normal dermis) that they are to replace. The materials which make up the

scaffold gradually degrade within the body, leaving behind a matrix of connective tissue with the appropriate structural and mechanical properties.⁷

The field of application of ADM, which was initially indicated and used in major burn injuries, has expanded to include reconstructive surgery by virtue of two properties: the possibility of incorporation by a “bridging effect”, which makes ADMs a possible simpler alternative to traditional skin flaps; and improvement in the qualities of STSG by the addition of dermis.⁸

The possibility of incorporation by a “bridging effect” requires the ADM to be applied to a partially vascularised bed. This property means that ADMs may be seen as an alternative to skin flaps on the reconstructive ladder, which are traditionally indicated to cover avascular wound beds.⁸

Improvement in the qualities of STSG is the reason for the use of ADMs in major burn injuries. The dermis of the skin is the main structure which explains its viscoelastic properties. Isolated STSG are less elastic than normal skin and are prone to greater secondary contracture formation during healing, whereas the addition of an ADM provides mechanical properties similar to healthy skin. The addition of an ADM also improves the cosmetic appearance of the grafts.⁸

Dermatofibrosarcoma protuberans is a soft tissue sarcoma which involves the dermis and underlying subcutaneous tissue. Features that are characteristic of DFSP are that they display slow infiltrative growth throughout their course, the potential for metastatic disease is little and they tend to have a high rate of local recurrence. DFSP is generally considered a low-grade lesion but those with fibrosarcomatous components on histological evaluation are deliberated as intermediate lesions.⁹⁻¹¹

Clinically DFSP is usually fixed to the dermis but is able to move over the underlying deeper structures. If deeper structures are involved, this usually indicates advanced disease or recurrence. Radiotherapy does have a role in the management of DFSP and it is usually considered when resection margins are close or still involved by tumour.⁹⁻¹¹

DFSP presents a complex challenge for the oncological and reconstructive surgeon because of its high rate of local recurrence. The first challenge is the adequate size of the margins; the second challenge is with regards to reconstruction.⁶

With regards to the reported case, a STSG was not an ideal immediate choice due to the structures which were exposed following the resection of the DFSP. While a STSG would have been able to cover the defect, the contours and deformities on the surface of the wound created by the exposed structures would have caused an unappealing result if a STSG only was applied. The ADM allowed for immediate coverage of the extensive and complex soft tissue defect, which would have otherwise required a STSG or free flap for closure. One of the considerations for using a fasciocutaneous flap to cover the neck is that it provided a more elastic form of coverage which would prevent contracture formation in a very mobile area of the body.

The healing process, with the ADM in place, occurred while the resected specimen was evaluated by the Pathology Department. We considered this another benefit of using an ADM in that it would allow for further surgical resection if any of the margins of the specimen were positive, and this would not significantly compromise the final reconstructive strategy. The ADM was used as a temporary cover for the wound; a STSG might have also been an option as a temporary cover while awaiting histological margins but should further resection be necessary, it would have resulted in wasted tissue and donor site morbidity.

The placement of the ADM allows for immediate coverage of large defects with a conservative strategy, preserving surrounding tissues. This means there is no need for the use of local flaps to achieve wound closure, as well as of other distant donor areas. This issue is of primary importance if one considers the high rate of local recurrences with DFSP and the potential need to preserve as many surgical options as possible for a second reconstructive surgery should further resection be required. The use of a full thickness skin graft over the neodermis created by the ADM was simply because the inferior abdomen had a large amount of excess skin which created an ideal donor site; this was coupled with the fact that the traditional STSG donor sites of this patient, i.e. from the thighs, were very small and the quality of skin harvested from these areas would have been of poor quality.

The adoption of a staged strategy offers the opportunity for an effective temporary coverage without immediate definitive reconstruction, which may represent a significant benefit if final histological examination requires a new excision of positive margins. The role of radiation therapy for adjuvant treatment in locally invasive cases is also a factor to consider when planning the reconstruction of the defects left after resection of DFSP. In these patients, temporary coverage could be achieved by means of an ADM during radiation therapy. While there is still emerging evidence and experience with regards to skin-graft-take on irradiated ADM, there seems to be no increase in postoperative complications, but this is still an area which needs further investigation.¹² There are a number of studies looking at the take of an ADM on a previously irradiated area with some optimistic evidence in that ADMs are currently being used successfully in the treatment of radiation ulcers, but once again the evidence for this practice is still emerging and needs further investigation.^{13,14} The use of an ADM allows for postponement of the final reconstruction until the end of the therapy so as not to affect the viability of reconstructed tissues.^{15,16}

There is evidence in the literature for the use of negative pressure wound therapy (NPWT) with ADMs, to accelerate the rate at which the neodermis integrates. In the reported case however, due to the position of the ADM on the cheek and face, NPWT was not applied.^{17,18}

Finally, given the incidence of this type of tumour in young adults, attention should be focused on the overall aesthetic outcome of reconstructive procedures and quality of life; ADMs provide an ideal recovery of the dermal layer, allowing a positive healing of skin grafts placed over it, for reasons already elucidated in this discussion.

The main disadvantage with ADM is that it is not a single-staged

procedure. Its application is simple but requires experience and follow-up facilities that allow for multiple weekly dressing checks.

Single-staged reconstructive dermal templates are now available and are appealing in theory and can be considered for small simple defects, however their use in more complex wounds such as described in this report remains to be seen.

The cost of the ADM product is also a significant factor, and the use of resources such as regular dressing changes should also be considered in the cost. This, however, has to be rationalised by the overall cost of treatment, for example when compared to the cost of alternative reconstructive options such as free tissue transfer which involves lengthy general anaesthetics and theatre occupancy and extended in-patient hospital stays. While these are important influencing factors in deciding the reconstructive course, the patient's autonomous decision must be given the most respect and should be the final consideration. While a free flap, at a centre which would be able to perform one, might have had a number of advantages over the chosen combined reconstruction, it was simply unacceptable for the patient and her decision to stay at our health facility in the Northern Cape was the ultimate deciding factor.

Conclusion

This presented technique provides a good reconstructive option for the management of soft tissue head and neck tumours which leave large defects following resection with curative objectives, particularly in settings such as ours where more complex reconstructive techniques are limited by a combination of factors.

References

1. Chalmers RL, Smock E, Geh JCL. Experience of Integra in cancer reconstructive surgery. *Journal of Plastic, Reconstructive & Aesthetic Surgery* (2010) 63, 2081e2090.

2. Jones I, Currie L, Martin R. A guide to biologic skin substitutes. *British Journal of Plastic Surgery* (2002), 55,185–193.
3. Burd A, Wong P. One-stage Integra reconstruction in head and neck defects. *Journal of Plastic, Reconstructive & Aesthetic Surgery* (2010) 63, 404e409.
4. Sartore L, Erica DV, Puppa AD, et al. Reconstructive strategies for dermatofibrosarcomas in the face: role of regenerative dermal templates. *Head & Neck*—DOI 10.1002/HED January 2015.
5. Berlotti E, Campagnari M, Molina A, et al. Artificial dermis (Matriderm) followed by skin graft as an option in dermatofibrosarcoma protuberans with complete circumferential and peripheral deep margin assessment. *International Wound Journal* © 2013 Medicalhelplines.com Inc and John Wiley & Sons Ltd.
6. Agostini T, Dini M, Quattrini Li A, et al. A novel combined surgical approach to head and neck dermatofibrosarcoma protuberans. *Journal of Cranio-Maxillo-Facial Surgery* 41 (2013) 681e685.
7. Boateng J, Catanzano O. Advanced therapeutic wound dressings for effective wound healing – A review. *Journal of Pharmaceutical Sciences* 104:3653–3680, 2015.
8. Pauchot J, Elkhyat A, Rolin G, et al. Dermal equivalents in oncology: benefit of one-stage procedure. *Dermatol Surg* 2013;39:43–50.
9. Dimitropoulos V. Dermatofibrosarcoma protuberans. *Dermatologic Therapy*, Vol. 21, 2008, 428–432.
10. Mendenhall W, Zlotnicki R, Scarborough M. Dermatofibrosarcoma protuberans. *CANCER* December 1, 2004/Volume 101/Number 11.
11. Goldberg C, Hoang D, McRae M, et al. A strategy for the successful management of dermatofibrosarcoma protuberans. *Annals of Plastic Surgery* Volume 74, Number 1, January 2015.
12. Israeli R, Feingold RS. Acellular dermal matrix in breast reconstruction in the setting of radiotherapy. *Aesthetic Surgery Journal*. 2011;31(7S):51S–64S.
13. Naseem S, Patel AD, Devalia H. Pioneering technique using acellular dermal matrix in the rescue of a radiation ulcer. *Il Giornale Di Chirurgia*, 37(1), 46–48.
14. Haubner et al. Wound healing after radiation therapy: Review of the literature. *Radiation Oncology* 2012 7:162.
15. Chao A, Sturgis E, Yu P, et al. Reconstructive outcomes in patients with head and neck sarcoma. *Head & Neck*—DOI 10.1002/HED May 2013.
16. Farma JM, Ammori JB, Zager JS, et al. Dermatofibrosarcoma protuberans: how wide should we resect? *Ann Surg Oncol* 17: 2112e2118, 2010.
17. Hadaegh A, Morykwas MJ, Shen P, Argenta LC. Acceleration of integra incorporation in complex tissue defects with subatmospheric pressure. *Plast Reconstr Surg* 113: 1339e1346, 2004.
18. Moiemens NS, Vlachou E, Staiano JJ, et al. Reconstructive surgery with integra dermal regeneration template: histologic study, clinical evaluation, and current practice. *Plast Reconstr Surg* 117: 160Se174S, 2006.